

## Navigated Laser Photocoagulation of Chronic Diabetic Macular Edema

Libor Hejsek<sup>1,4</sup>, Alexandr Stepanov<sup>1,4</sup>, Jaroslava Dusová<sup>1,4</sup>, Jan Studnička<sup>1,4</sup>, Jan Marák<sup>1,4</sup>, Jan Beránek<sup>1,4</sup>, Naďa Jirásková<sup>1,4</sup>, Pavel Rozsival<sup>1,4</sup> and Ján Lešťák<sup>2,3,4\*</sup>

<sup>1</sup>Department of Ophthalmology, University Hospital and Charles Medical Faculty, Hradec Králové, Czech Republic

<sup>2</sup>JL Clinic, V Hurkách 1296/10, Prague, Czech Republic

<sup>3</sup>Faculty of Biomedical Engineering, Czech Technical University in Prague, Czech Republic

<sup>4</sup>Faculty of Medicine in Hradec Kralove, Charles University, Czech Republic

\*Corresponding author: Prof. MUDr. Jan Lešťák CSc., FEBO, JL Clinic, V Hůrkách 1296/10, Prague, Czech Republic, Tel: +420 296 186 113; E-mail: [lestak@seznam.cz](mailto:lestak@seznam.cz)

Received date: Jan 16, 2015, Accepted date: Mar 28, 2015, Published date: Mar 31, 2015

Copyright: © 2015 Hejsek L, et al. This is an open-access article distributed under the terms of the Creative Commons Attribution License, which permits unrestricted use, distribution, and reproduction in any medium, provided the original author and source are credited.

### Abstract

**Objective:** This paper deals with a retrospective evaluation of the effect of navigated photocoagulation of chronic DME with the NAVILAS device.

**Methods:** The cohort comprised 18 eyes with clinically significant DME. The age range was 41-82 years (median 68) and the monitoring time in all eyes lasted for 12 months. The following examination techniques were employed: best corrected visual acuity (BCVA) tested on ETDRS charts, biomicroscopic examination of the fundus in artificial mydriasis, colour photography, fluorescent angiography (FAG), and optical coherence tomography (OCT, spectral domain Cirrus, C. Zeiss). The values of BCVA and OCT were statistically tested by means of a non-parametric pair test (Wilcoxon). The performed therapy included 1 focal laser treatment of the macula, 9 grid photocoagulations of the macula, and 8 direct photocoagulations of leaking microaneurysms. Laser treatment was done using navigated photocoagulation by NAVILAS device.

**Results:** The initial BCVA ranged between 0.1 and 0.8 (average 0.5); at the end of the monitoring period the range of BCVA was 0.1 to 1.0 (average 0.5). No statistically significant difference was found between the pre-operative and post-operative values of BCVA. The average value of the thickness of the macula in the central field on OCT was 360  $\mu$ m prior to the intervention and 322  $\mu$ m at the end of the monitoring time. This difference was statistically significant ( $p=0.015$  Wilcoxon). After laser treatment with a NAVILAS device there was an anatomical improvement in DME. The sight functions (BCVA) remained stabilized.

**Conclusion:** Navigated photocoagulation of the macula for DME showed in the present cohort of patients a favourable and functional benefit of the used method.

**Keywords:** Diabetic macular edema; DME; Photocoagulation; NAVILAS

### Introduction

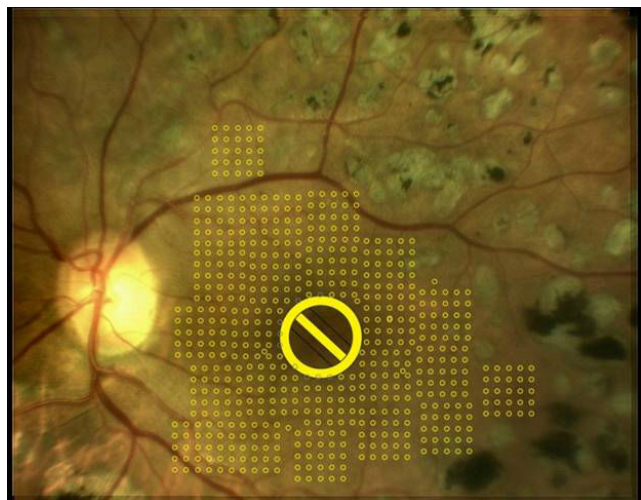
Since its discovery in the 1940s, great advances have been made in laser photocoagulation of the retina. At present new possibilities for the use of this technique are being found based on various modifications (time-in the sense of a possible micropulse regimen; space-in the sense of the use of active eye-tracking; wave-in the sense of the use of different colours of laser light; etc.). Modern devices do not produce large photocoagulation scars and atrophies. On the contrary, they are able to make use of precise targeting, subthreshold treatment or photostimulation.

Conventional lasers utilize high-energy light, which is converted to heat energy after absorption by the tissue. If the temperature at the site of intervention and its near surroundings exceeds 65 degree Celsius, denaturation of cell proteins develops with coagulation necrosis. An accompanying phenomenon can be gradual spread of atrophy of the retinal pigment epithelium (RPE) and neuroretina. Photocoagulation

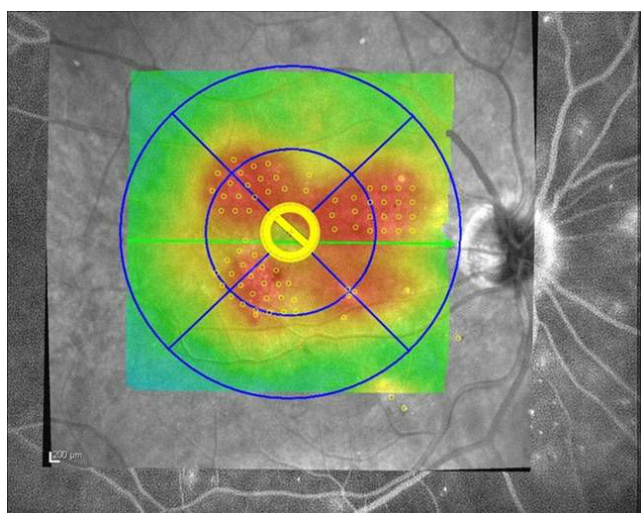
traces then result in the development of scotomata in the central part of the visual field.

There are currently two trends which limit the destructive effect of laser intervention: 1) subtle and targeted treatment of only the pathological sites using a device with a navigated beam (the device NAVILAS, OD-OS Inc., USA), and 2) limitation of thermal impairment of the tissue with a micropulse laser regimen.

Navigated laser photocoagulation using active eye-tracking makes it possible to increase the precision of the intervention and to treat only the necessary sites. The NAVILAS device carries out photocoagulation automatically on the basis of a pre-prepared plan. Planning of an intervention we can make by usage: infrared photography, colour photography (Figure 1), and fluorescent angiography. All these examinations can be performed with the NAVILAS device prior to an intervention. Imported images of angiography or maps from optical coherence tomography can be used (the laser software is able to superpose them on its native image) (Figure 2).



**Figure 1:** Planning of an intervention shown in a colour photograph of the eyegrounds (the plan shows a grid with traces of size 50 µm excluding the foveal region).



**Figure 2:** Planning of an intervention in fluorescent angiography of the eyegrounds and simultaneously according to the topical edema on OCT (the plan shows a grid with traces of size 50 µm excluding the foveal region, in the inner lower quadrant leaking microaneurysmata are shown).

DME is the main cause of loss of visual acuity in patients with diabetes mellitus and the leading cause of sight loss in those of active age in advanced countries. With the increase of diabetic patients, so also are increased the patients with sight affections and their treatment costs. In 2004 The World Health Organization (WHO) estimated an increase in diabetic patients from 171 million in the year 2000 to 366 million in the year 2030, when DME could affect 4.4% of the world population [1]. New data form year 2013 indicate, that 8.3% of the adult population has diabetes and 38.2% has abnormal fasting glucose levels or prediabetes [2].

Laser therapy of the retina in DME has been “the gold standard” of therapy in the past thirty years. The importance of laser intervention rather lies in stabilization of retinopathy and the avoidance of blindness. An improvement in visual acuity after photocoagulation treatment is not the rule and in diffuse edemas is rather rare [3-5]. For these reasons there are drugs with higher efficacy (injectable corticoids and anti-VEGF) [6]. However, at present, unlike laser, they are not fully available for all diabetic patients. The reason is the high price of these preparations and the limits on indication for their use.

All types of therapy require good compensation of principal diseases [7].

This paper aims to present the effect of navigated photocoagulation of chronic DME using a NAVILAS device.

## Materials and Methods

A retrospective evaluation included a cohort of 18 eyes (13 patients) who were monitored for 12 months after navigated photocoagulation of the macula with a NAVILAS device. The indication for the performance of treatment was a chronic clinically significant DME in patients who did not fulfil the indication limits for funding of intravitreal injection therapy. The reasons for non-fulfilment of the indication conditions for funding of anti-VEGF therapy were as follows: a level of glycated hemoglobin higher than 6.0% (HbA1c < 6.0% according to IFCC or HbA1c < 60.0 mmol/mol), or a demonstrated period of duration of DME longer than one year. The monitored eyes did not exhibit pathology of the vitreoretinal interface according to OCT.

The following examination procedures were used: best corrected visual acuity (BCVA) tested on ETDRS optotype tables, biomicroscopic examination of the fundus in artificial mydriasis, colour photography of the fundus, fluorescent angiography (FAG) and optical coherence tomography (OCT, Cirrus). The values of BCVA and OCT were statistically tested by means of non-parametric pair test (Wilcoxon). Compensation of diabetes was evaluated according to glycated hemoglobin (HbA1c).

## Description of the laser therapy method

A colour photograph of the eyegrounds is taken using the NAVILAS device. If needed, FAG is recorded. The colour photograph (it can be combined with a FAG picture or a map of the macula from OCT) is used to formulate the plan of the intervention: the position of laser points is selected, along with their required size and the duration period of the trace. It is possible also to mark the areas which, in contrast, are not intended to be lasered. A contact lens, which is supplied with the device, is then placed on the eye. If the patient cooperates, it is possible to perform the intervention without the lens. According to the reaction of the tissue, the required energy of the laser trace is selected and the whole planned treatment is then carried out automatically by the device. The device makes use of a wavelength of 532 nm. The size of the trace which falls on the retina really corresponds to the size of the planned trace. Whilst most laser lenses for routine photocoagulation increase the size of the trace, NAVILAS produces really subtle unobtrusive treatment with small traces at regular intervals.

## Results

The cohort consisted of 18 eyes (in 13 patients). The age distribution of the patients ranged from 41 to 82 years (median 68) and included 3 males and 10 females. Only 2 patients (15%) suffered from diabetes mellitus type 1. The demonstrated period of total disease ranged from 6 to 30 years (median 19 years). Four patients (31%) were

being treated with oral antidiabetic agents, eight patients (62%) with insulin, and one (7%) with a combination. During the year-long monitoring, glycated hemoglobin ranged from 5.5 to 10% (average 7.5%). The type of diabetic retinopathy, specification of edema, a survey of previous therapy of DME, and a list of concomitant diseases are shown in Table 1.

Patient number	Age	Diabetes mellitus type	Duration period of DM (years)	Principal therapy DM	Average compensation according to HbA1c	Type of diabetic retinopathy	Type of diabetic macular edema	Previous therapy of DME	Concomitant diseases
1	68	2	6	PAD	5.50%	Nonproliferative	Diffuse	3x focal laser of the macula	Decompensated arterial hypertension
2	73	2	20	INZ	8%	Risk nonproliferative	Diffusion ischemic	PRF, 4x focal laser	Arterial hypertension
3	68	2	18	INZ	7.40%	Nonproliferative	Diffuse	Incomplete GRID OPL	Arterial hypertension, hyperlipidaemia
4	77	2	19	INZ	8.20%	Nonproliferative	Diffuse	Incomplete GRID OPL	Arterial hypertension, hyperlipidaemia, stroke
5	56	2	10	PAD	9.40%	Nonproliferative	Focal	3x focal laser of the macula	Asthma
6	82	2	25	INZ	6.50%	Risk nonproliferative	Diffuse	2x focal laser of the macula, incomplete PRF	Arterial hypertension, hyperlipidaemia
7	69	1	30	INZ	10%	Proliferative	Diffuse	PRF left	Arterial hypertension, ischemic heart disease, peripheral arterial disease, right lower limb amputation
8	57	2	7	PAD	6.80%	Nonproliferative	Diffuse	3x focal laser of the macula, 4x study medication (Ozurdex/placebo)	0
9	56	2	10	PAD+INZ	9.30%	Proliferative	Focal	PRF	Arterial hypertension
10	70	2	24	PAD	5.60%	Nonproliferative	Focal	1x focal laser of the macula	Ischemic heart disease
11	45	1	30	INZ	5.60%	Risk nonproliferative	Diffuse	2x focal laser of the macula, incomplete PRF	Arterial hypertension, frequent hypoglycaemias
12	75	2	19	INZ	6.20%	Nonproliferative	Diffuse	2x focal laser of the macula	Arterial hypertension, hyperlipoproteinaemia, operation of valvular defect
13	65	2	25	INZ	8.50%	Nonproliferative	Focal	2x focal laser of the macula	Arterial hypertension, heavy obesity, diabetic foot

**Table 1:** Characteristics of the cohort.

Laser treatment of DME was carried out to the planned extent in all patients without complications. Of the performed treatments, one was supplemented focal laser treatment, 9 were grid photocoagulations of the macula (GRID), and 8 direct photocoagulations of leaking microaneurysmata in different parts of the macula (Table 2).

The initial BCVA ranged between 20/200 and 20/25 (average 20/40). At the end of the 12-month follow-up BCVA ranged from 20/200 to 20/20 (on the average slightly worse than 20/40). No statistically significant difference was found between the preoperative

and postoperative values of BCVA. The average value of the thickness of the macula in the central field on OCT was 360  $\mu$ m prior to the intervention and 322  $\mu$ m at the end of the follow-up period. This difference was statistically significant ( $p=0.015$  Wilcoxon). During the follow-up period no complications developed on the front segment of the eyes under examination: no progression of cataract was observed, no neovascularizations developed on the iris, and no secondary glaucoma was observed.

Patient number	Type of laser therapy of DME	BCVA prior to laser OP	BCVA prior to laser OL	BCVA after laser OP	BCVA after laser OL
1	OP-macula focally	0.1	-	0.1	-
2	OPL-GRID	0.4	0.3	0.625	0.25
3	OPL-GRID	0.6	0.4	0.6	0.4
4	OPL-laser of microaneurysms	0.5	0.6	0.625	0.625
5	OP-laser of microaneurysms	0.6	-	0.8	-
6	OPL-GRID	0.25	0.4	0.25	0.4
7	OL-GRID	-	0.1	-	0.1
8	OL-laser of microaneurysms	-	0.25	-	0.6
9	OP-laser of microaneurysms	0.6	-	1.0	-
10	OP-GRID	0.8	-	0.8	-
11	OP-GRID	0.80	-	1.0	-
12	OPL-laser of microaneurysms	0.6	0.6	0.8	0.8
13	OL-laser of microaneurysms	-	0.6	-	0.6

**Table 2:** Survey of performed treatments with the development of BCVA.

## Discussion

Intravitreal DME treatment, particularly in the case of anti-VEGF therapy, is anatomically and functionally very effective. Its widespread use is, however, limited by the financial realities and indication criteria in some countries. The numbers of diabetic patients and patients suffering from DME in spite of their efforts to achieve strict glycaemic control together with the compensation of hypertension and hyperlipidaemia are continually growing, and our ability to fund intravitreal treatment is limited. For this reason, laser treatment of DME remains the gold standard of therapy. Another therapeutic solution to DME is surgery via PPV, which reliably decreases macular edema and stabilizes retinopathy [8].

Laser therapy may result in anatomical and subsequently also functional complications, which include: atrophic foci of the macula, hypertrophic clusters of RPE, wide-spread progression of both previous changes, fibrotization in the macula, etc. These side effects of photocoagulation (in particular collateral progression of photocoagulation traces) limit visual function by the development of irreversible central scotomata. Limitation of these complications can be achieved by detailed, subtle and precise treatment of only absolutely necessary sites with automatically navigated laser. Influence of navigated laser treatment for the eventual development of scotoma was not evaluated in this paper.

The present paper evaluates a cohort of eyes with DME in a one-year follow-up after treatment with targeted and precise laser intervention. The size of the cohort was constrained by the short lending period of the laser device. Navigated photocoagulation therapy of eyes affected by DME was indicated when the patient failed to fulfil our local (Czech republic) indication limitation required for funding

of anti-VEGF therapy, and no clinically significant pathology of the vitreoretinal interface on OCT was present. Statistically significant improvement of the chronic macular edema on OCT was not accompanied by an improvement in BCVA. The reasons for this finding are multifactorial, as well as the development of DME itself. The principal cause of a low functional effect is assumed to be the long-term duration of macular changes. Navigated photocoagulation in active eye-tracking excludes unwanted photocoagulation of the foveola, so there is no danger that it is immediately affected. The patient with impaired function of the foveola can nevertheless make use of a near eccentrically localized focus of the hitherto relatively well functioning neuroretina, which may be impaired by the laser. We presume this phenomenon in the patient number 2.

In the study group of 18 eyes with chronic DME had already 16 eyes (88.9%) performed photocoagulation in the macula in the previous time. Navigated laser therapy was performed in 17 cases according to the plan without FAG, just using to native photographs and superimposed OCT scans. Therefore, we do not evaluate the effect of NAVILAS to leakage during FAG controls either. All treatments had no side effects, neither early, nor late complications developed. Patients tolerated the treatment very well.

Our finding of a decrease in central macular thickness by-38 µm is assessed as rather a stabilization of the condition, also with regard to the fact that after laser treatment the macular thickness is not usually decreased markedly. Browning et al. in their paper report a decrease by-28 µm at the end of a 6-month follow-up [9]. Photocoagulation according to the modified protocol ETDRS offers a potential decrease in macular edema on average of -88 µm in the stabilization of BCVA, i.e. without improvement of visual acuity in a 12-month follow-up period [10]. Also, according to the recent result of the DRCS.net study (photocoagulation therapy of DME with a modified protocol ETDRS), the majority of lasered eyes have a rather stable finding: 19% had losses >10 letters of BCVA and 32% improved by more than 10 letters of ETDRS [11]. A higher probability of decrease in visual acuity after laser therapy was observed in DME with a higher thickness of the macula. These DME had most probably persisted for a longer time, and for a sufficient photocoagulation effect a higher energy of laser had to be used. On the other hand, the best effect of photocoagulation was observed in the findings with a decrease in visual acuity with a smaller thickness of swelling-most probably the originating states of DME. The authors unfortunately do not define the unambiguous value of the thickness of the retina suitable for laser therapy.

A great advantage of navigated treatment with active eye-tracking is the possibility of treatment in the vicinity of vulnerable structures (central part of the macula, fine vessels at the extended margins of a defective foveal vascular zone) and targeted treatment of one site with a small trace (e.g. a leaking microaneurysm). The precision of treatment with NAVILAS has been demonstrated by Kozak, who published a 92% probability of a correct intervention into a microaneurysm by a single trace. With the use of a conventional laser by an experienced specialist this probability is only 72%, with the added precondition of a well-cooperating patient [12].

The plan and the sites of performed traces are a component of the outlet protocol about the performed procedure and serve for possible planning of subsequent photocoagulations. Other sessions are then not performed on already treated sites, thus limiting the risk of progression of photocoagulation scars.

## Conclusions

Navigated photocoagulation of the macula for chronic DME showed in the present cohort of patients a favourable and functional benefit of the method employed. A great advantage of this type of intervention is the potential for detailed and individualized performance of treatment, minimization of risks of unwanted photocoagulation of vulnerable sites, and perfect documentation of the localization of performed traces. The principal limitation of the present paper is the small size of the cohort.

Modern laser devices are exact and safer while preserving the efficacy of photocoagulation. Laser therapy can be combined with anti-VEGF therapy and surgery.

## Acknowledgement

All co-authors have read the final manuscript within their respective areas of expertise.

## References

1. Wild S, Roglic G, Green A, Sicree R, King H (2004) Global prevalence of diabetes: estimates for the year 2000 and projections for 2030. *Diabetes Care* 27: 1047-1053.
2. Santulli G (2013) Epidemiology of cardiovascular disease in the 21st century: updated numbers and updated facts. *JCvD* 1: 1-2.
3. [No authors listed] (1985) Photocoagulation for diabetic macular edema. Early Treatment Diabetic Retinopathy Study report number 1. Early Treatment Diabetic Retinopathy Study research group. *Arch Ophthalmol* 103: 1796-1806.
4. Diabetic Retinopathy Clinical Research Network (2008) A randomized trial comparing intravitreal triamcinolone acetonide and focal/grid photocoagulation for diabetic macular edema. *Ophthalmology* 115: 1447-1459.
5. Beck RW, Edwards AR, Aiello LP, Bressler NM, et al. (2009) Three-year follow-up of a randomized trial comparing focal/grid photocoagulation and intravitreal triamcinolone for diabetic macular edema. *Arch Ophthalmol* 127: 245-251.
6. Kousal B, Kalvodova B (2014) Aflibercept in terms of ophthalmology. *Remedia* 24: 428-433.
7. Veith M (2013) [Treatment of diabetic macular oedema in a type 1 diabetes patient--mistakes in interdisciplinary collaboration]. *Vnitr Lek* 59: 231-233.
8. Navarro A, Pournaras JA, Hoffart L, Massin P, Ridings B, et al. (2010) Vitrectomy may prevent the occurrence of diabetic macular oedema. *Acta Ophthalmol* 88: 483-485.
9. Browning DJ, Fraser CM, Powers ME (2006) Comparison of the magnitude and time course of macular thinning induced by different interventions for diabetic macular edema: implications for sequence of application. *Ophthalmology* 113: 1713-1719.
10. Fong DS, Strauber SF, Aiello LP, Beck RW, et al. (2007) Comparison of the modified Early Treatment Diabetic Retinopathy Study and mild macular grid laser photocoagulation strategies for diabetic macular edema. *Arch Ophthalmol* 125: 469-480.
11. Aiello LP, Edwards AR, Beck RW, Bressler NM, Davis MD, et al. (2010) Factors associated with improvement and worsening of visual acuity 2 years after focal/grid photocoagulation for diabetic macular edema. *Ophthalmology* 117: 946-953.
12. Kozak I, Oster SF, Cortes MA, Dowell D, Hartmann K, et al. (2011) Clinical evaluation and treatment accuracy in diabetic macular edema using navigated laser photocoagulator NAVILAS. *Ophthalmology* 118: 1119-11124.