



## Functional Mri After Internal Limiting Membrane Peeling for Symptomatic Lamellar Macular Hole and Macular Pseudoholesurgery

### KEYWORDS

lamellar macular hole, macular pseudohole, EMM and ILM peeling, fMRI

#### Jan Lestak

Charles University (Faculty of Medicine in Hradec Králové), Simkova 870, Hradec Kralove, Czech Republic

#### Jaroslav Tintera

JL Clinic, V Hůrkách 1296/10, Prague, Czech Republic

#### Jan Kalvoda

Charles University in Prague (Department of Ophthalmology, First Faculty of Medicine and General University Hospital in Prague), U nemocnice 2, Prague, Czech Republic

#### Zuzana Svata

JL Clinic, V Hůrkách 1296/10, Prague, Czech Republic

#### Bohdana Kalvodova

Charles University in Prague (Department of Ophthalmology, First Faculty of Medicine and General University Hospital in Prague), U nemocnice 2, Prague, Czech Republic

#### Ivan Karel

JL Clinic, V Hůrkách 1296/10, Prague, Czech Republic

#### Pavel Rozsival

Charles University (Faculty of Medicine in Hradec Králové), Simkova 870, Hradec Kralove, Czech Republic

**ABSTRACT** *The aim of the study was to determine whether the epimacular membrane (EMM) and internal limiting membrane (ILM) peeling for symptomatic lamellar macular hole (LMH) and macular pseudohole (MPH) will lead to reduction of functional MRI (fMRI) response in the visual cortex of the brain. The pilot study involved 20 eyes of 10 patients (7 female and 3 male) with a mean age of 75 (66–83 years) who underwent pars planavitrectomy. The other eye served as a control. Patients did not suffer from any other ocular or neurological disease. All the patients underwent fMRI examinations with stimulation of both eyes separately using an alternating black and white checkerboard. The number of activated voxels in the visual cortex gained for each eye was compared by means of standard data evaluation using the general linear model (T-map threshold of  $P=0.05$  with family-wise error correction), and paired T-test was used for statistical evaluation of this difference.*

*All patients showed a decrease of fMRI brain activation after stimulation of the eye where surgical intervention was performed. The analysis showed a statistically significant difference between the operated and non-operated eye ( $P=0.0049$ ). Patients with symptomatic partial macular defects after EMM and ILM peeling showed a decrease of the fMRI brain activity after stimulation of the operated eye.*

### Introduction

Müller (radial glial) cells span the entire thickness of the retina, and contact and sheath every type of neuronal cell body and process. Their internal processes merge into the internal limiting membrane. This morphological relationship is reflected by a multitude of functional interactions between retinal neurons and Müller cells, including extracellular ion homeostasis and glutamate recycling by Müller cells. Müller cells are key mediators of nerve cell protection, especially via release of basic fibroblast growth factor, via uptake and degradation of the excitotoxin glutamate, and via secretion of the antioxidant glutathione. Neovascularisation during hypoxic conditions is mediated by Müller cells via release of vascular endothelial growth factor and transforming growth factor beta or via direct contact to endothelial cells [1].

Peeling of the internal limiting membrane (ILM) of the retina has been proved beneficial for increasing the anatomic success rate of symptomatic partial macular defects (PMD) surgery [2-6]. Despite this favourable outcome, the question

whether peeling can cause damage to the visual functions still remains subject of discussion. There is no doubt that the removal of a portion of Müller cells can not only cause damage to the Müller cells themselves, but also disrupt metabolic processes in the retina, especially in the nerve fibre layer of retinal ganglion cells. While most studies deal with visual acuity or retinal function after ILM and EMM peeling, the aim of our study was to determine whether peeling may damage the brain visual function and so affect the fMRI activation in this region.

### Materials and Methods

The pilot study involved 20 eyes of 10 patients (7 female and 3 male) with a mean age of 75.1 years (66–83 years) who underwent pars planavitrectomy between January 2009 and October 2009 for symptomatic lamellar macular hole (LMH)—four patients, macular pseudohole (MPH)—three patients, and epimacular membrane (EMM)—three patients [6]. Assessment of LMH and MPH was based on the definition of Witkin et al. [7] and Haouchine et al. [8]. The other eye of our patients served as a control (see Table 1). Pa-

tients did not suffer from any other ocular or neurological disease.

No.	Sex/ Age	VA before RE/LE	VA after RE/LE	fMRI (number of voxels)			OCT	Clinical diagnosis	Peeling	Time after surgery
				RE+LE	RE	LE				
1.	F/66	1.0/0.1	1.0/0.6	2 500	4 900	1 600	EMM	EMM	LE	4
2.	F/68	0.3/0.6	0.4/0.6	6 760	4 600	5 450	LMH	LMH	RE	4
3.	F/73	0.7/1.0	0.5/1.0	2 350	100	1 450	EMM	EMM	RE	4
4.	F/80	0.4/0.8	0.2/0.8	6 700	4 700	5 800	LMH	IMD	RE	4
5.	F/80	0.2/0.6	0.4/0.6	1 500	1 500	1 700	LMH	IMD	RE	4
6.	F/83	0.8/0.5	0.8/0.5	2 164	3 000	1 545	EMM	EMM	LE	4
7.	F/83	1.0/0.8	1.0/0.2	3 100	7 700	5 400	MPH	EMM	LE	4
8.	M/60	1.0/0.2	1.0/0.5	1 500	2 200	2 060	LMH	EMM	LE	3
9.	M/75	0.3/0.7	0.3/0.7	5 600	7 170	7 250	MPH	EMM	RE	4
10.	M/83	1.0/0.8	1.0/0.8	6 300	3 950	2 900	MPH	EMM	LE	4

**Table 1.** Summary table for all patients. EMM – epimacular membrane, LMH – lamellar macular hole, MPH – macular pseudohole, IMD – idiopathic macular defect, ILM – internal limiting membrane

Surgery	Average number of the active voxels	Standard deviation
yes	3 157	2 210.6
no	4 340	2 243.1

**Tab. 2.** The table shows the average number of statistically significant voxels of the fMRI response and its standard deviation in operated (Surgery: yes) and control eyes (Surgery: no).

**Surgical techniques**

Under local anaesthesia and/or sedation analgesia, patients underwent 3-port triamcinolone-assisted 23-gauge PPV with separation, elevation and removal of the posterior vitreous cortex. In all treated eyes, suspension of triamcinolone acetonide 40 mg (TA) was applied to the vitreous body to visualise the vitreous gel. Surgical separation of the posterior plane of the vitreous body was initiated by suction with an aspirating vitrectomy probe (Acurus, Alcon, USA), while the separation of the vitreous body from the optical nerve papilla was confirmed by elevation of the Weiss glial ring [9,10]. To visualise the residual posterior vitreous cortex we used the approach described by Sonoda et al. [11] and Doi et al. [12]. Approximately 0.5 ml of triamcinolone acetonide suspension was injected into the midvitreous cavity. The triamcinolone granules were trapped in the structure of residual vitreous cortex, which was typically seen on the macula as either a diffuse membrane or small islands. The residual vitreous cortex was then aspirated by Charles aspirator with silicone brushes. To visualise the EMM and ILM, we used 0.15% trypan blue (Membrane Blue, D.O.R.C. International, Rotterdam, the Netherlands) (TB). The trypan blue solution was applied to the retina and the infusion was temporarily stopped. After 60 seconds, the infusion was resumed and the dye was removed. For EMM and ILM peeling, we used a special micro forceps and the place for the initial grip was selected

close to the EMM margin, also with regard to the preoperative OCT finding. ILM of the retina was removed in all eyes, often unintentionally together with EMM. Immediately after peeling, the EMM and ILM were fixed in 2.5% glutaraldehyde and sent to further processing under electron microscopy. For subsequent processing of the collected tissues we used the approach described by Kalvoda et al. [13].

**Functional MRI**

Functional MRI examinations were carried out on the Philips Achieva 3T TX MR system (Philips Healthcare, Eindhoven, Netherlands) operating with a magnetic field strength of 3 Tesla using the BOLD method. A standard 32-channel SENSE head RF coil was used for scanning. For fMRI measurements based on the BOLD technique, the gradient-echo EPI sequence was used with the following parameters: TE = 30ms, TR = 3s, flip angle of 90°. The measured volume contained 39 continuous slices. The voxel size measured was 2x 2x 2mm (FOV = 208x 208mm, matrix 104x104, SENSE factor 1.8).

Optical stimulation was provided by a black/white checkerboard alternated with its negative image with a frequency of 2 Hz. The visual size of the black and white checkerboard was 25.8 x 16.2 degrees. The measurements consisted of a sequence of five 30-second active phase periods and five resting periods of the same length (each of 10 dynamic scans). During the resting phase, a static cross-hair situated in the centre of the visible field was projected for the view fixation. In total, every measurement included 100 dynamic scans and took 5 minutes. Each eye was examined by means of separate fMRI measurement (LE, RE) and also one control measurement was performed by stimulating both eyes together (LE+RE).

The obtained data were processed using SPM8 software and general linear model (GLM). During the pre-process, the data were motion corrected (realignment), corrected for time-shift of individual slices (slice timing), then smoothed using a Gaussian filter with FWHM of 6 x 6 x 6 mm and finally normalized into the MNI\_152 space. For individual statistics, the GLM with canonical hemodynamic response function (HRF) applied to the block scheme of the stimulation was used. Statistical maps were thresholded at the level of P = 0.05 with FWE correction.

The number of activated voxels in the visual cortex gained for each eye in the thresholded t-map was compared and paired t-test was used for statistical evaluation of this difference.

**Results**

The ultrastructural morphometry of the eyes with partial macular defects and EMM yielded the following results:

Histopathological examination of EMM and ILM in all ten eyes showed fibroblasts, collagen ligaments, extracellular matrix, and macrophages in one or more layers of the vitreous surface of ILM. ILM morphometry confirmed its thickness to 3.98 ± 0.86 µm (range 3.28 – 5.92 µm).

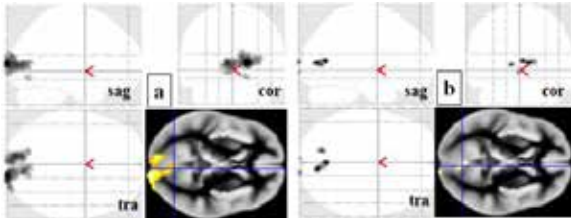
Visual acuity was improved in four eyes, deteriorated in three eyes and remained unchanged in three eyes during the follow-up interval of three to four years after surgery.

**fMRI results**

All eyes where surgical intervention was performed showed lower activity during the fMRI examination compared to

the control non-operated eye (see Tables 1 and 2). This difference expressed in the amount of statistically significant voxels corresponding to the stimulation was in the range of 1–93% (untreated eye used as a reference). However, the asymmetry in activation higher than 15% was found in seven out of 10 subjects and the average difference was 27%.

The fMRI results of the patient with the highest activation difference between both eyes from our group are shown in Figure 1 (subject No. 3).



**Figure 1. Thresholded T-maps of the patient No. 3, who underwent ILM peeling of the right eye for EMM. Sagittal, coronal and transversal projections show the activity of the visual cortex after stimulation of the a) left eye (1450 voxels) and b) right eye (100 voxels).**

## Discussion

To our best knowledge, the literature provides no reports of fMRI examination after ILM and EMM peeling in patients with LMH, MPH or IMD.

Trans-synaptic neuronal degeneration and damage to ganglion cells in the visual cortex can be expected in cases of retinal ganglion cell damage. This was also demonstrated by studies on patients with hypertensive glaucoma [14–16] and age-related macular degeneration [17, 18]. Conversely, Nguyen et al. [19] and Baseler et al. [20] discovered increased fMRI activation in patients with AMD. Our comment on the possible explanation of this finding has been published recently [18].

In this study, we anticipated a similar mechanism of possible visual cortex damage as well. In the case of retinal ganglion cells, the damage, either directly to their axons or indirectly via Müller cells of the retina, can affect the visual cortex due to transneuronal degeneration at a certain point of time.

Possible damage to the retina after PPV with peeling was documented by a number of studies reporting on the anatomical and functional changes after variable periods of time following the procedure. Baba et al. [21] found a reduction in the layer of ganglion cells on OCT at three- and six months after PPV with peeling. A similar conclusion was made by Kumagai et al. [22]. The authors examined 24 eyes after ILM peeling for MH and found a significant reduction in the mean retinal thickness as early as one month after the surgery, and this reduction continuously progressed during the 24 month of follow-up, with the exception of nasal retina where the procedure was not carried out.

In contrast, Sevim and Sanisoglu [23] did not notice any difference in the thickness of the layer of ganglion cells before and six months after the macular hole surgery with or without ILM peeling.

Changes in the nerve fibre layer after peeling for MH was

studied by Clark et al. [24]. During the first month after surgery, they noted oedema of the nerve fibre layer, which resolved after two months. This finding had no effect on visual acuity.

In this context, attention should be paid to the study of Lesnik, Oberstein et al. [25], who employed immunohistochemistry to examine the epiretinal membranes obtained by peeling and anti-neurofilament-labelled neurites, presumed to originate from ganglion cells, which were found in all 32 idiopathic epiretinal membranes examined.

Functional changes after PPV with ILM peeling were reported in a study by Tsuka et al. [26]. Perimetry findings in 140 eyes, which were subject to vitrectomy with ILM peeling (assisted ICG) for macular hole, were retrospectively studied and the findings included nasal defects in 11 eyes, temporal visual field defects in seven eyes and a concentric narrowing in one eye.

Tadaoni et al. [27] used microperimetry to examine 16 eyes that were subject to idiopathic macular hole surgery. Eight eyes where peeling was carried out showed a greater reduction in retinal sensitivity compared to eight eyes where the surgery was performed without ILM peeling.

Terasaki et al. [28] performed focal macular ERGs six weeks and then again six months after the successful closure of the hole and discovered that the percentage increase in the b-wave amplitude was significantly higher in the ILM-on group (44.0%) than in the ILM-off group (15.0%,  $P = 0.037$ ) six months after the surgery.

Although the above studies illustrate possible damage to the retina during ILM peeling, most authors agree that peeling is the most beneficial procedure in macular surgery. The financial aspects of surgery with peeling should also be emphasised. Although Spiter-Cornish et al. [29] found no evidence of a benefit of ILM peeling in terms of the primary outcome (visual acuity at six months), ILM peeling appears to be superior to its no-peeling counterpart as it offers more favourable cost effectiveness by increasing the likelihood of primary anatomical closure and subsequently decreasing the likelihood of further surgery with no differences in unwanted side-effects compared with no peeling.

The possible cytotoxic effect on retinal ganglion cells should be taken into account during PPV and ILM peeling with intravitreal administration of TA. Jaissle [30] reported a case of optic atrophy with central visual field defect and severe reduction of the visual acuity to hand movements in a patient after PPV with ILM peeling for macular pucker and re-vitrectomy with intravitreal injection 25 mg TA due to a secondary macular pucker with cystoid macular oedema.

In our patients, TA was always thoroughly removed during vitrectomy and its adverse effect on retinal structures is considered highly unlikely.

There are no studies of anterograde transneuronal degeneration in the sense of the time required for the retinal stimulus to reach cortical ganglion cells, and it can only be estimated to be longer than 12 months. In our patients, functional MRI was performed 3–4 years after PPV with peeling, and all patients had lower fMRI activity after light stimulation of the operated eye.

During our previous study with a healthy control group we found the average interocular difference in activation to be 2.2%, and this difference was not statistically significant ( $P=0.85$ ). However, the average difference in case of our patients after peeling was 27.3% and additionally, in all patients we found a decrease in fMRI brain activation specifically after the stimulation of the operated eye ( $P=0.0049$ ).

These results support our initial assumption that ILM peeling can also lead to damage to the ganglion cells of the brain visual cortex, but without affecting the visual acuity. However, we can only speculate to what extent the decrease of the brain activation is caused either due to lower input of action potentials from the altered retinal ganglion cells or due to possibly damaged cells in the brain cortex.

#### LIMITATION OF THE STUDY

In our present study we cannot exclude the possible influence of pre-surgery retinal abnormalities on fMRI activity. We could only use a fellow eye as a control of activation. However, in our recent paper investigating the inter-ocular variability of fMRI response we found an average difference between normal left and right eye to be 2.2%. The inter-ocular average difference in the case of patients from the present study was much higher (27.3%).

To exclude the mentioned influence of the pre-surgery retinal state, we currently perform pre-operative fMRI examination followed by long-term post-operative follow-up by means of fMRI.

The study protocol was approved by the local Ethics Committee and the study was performed in accordance with Good Clinical practice and the Declaration of Helsinki.

This study was supported by the Research programme of Charles University P25/LF1/2.

#### REFERENCE

- Bringmann A, Reichenbach A. Role of Müller cells in retinal degenerations. *Front Biosci*2001;6:72-92 | 2. Garretson BR, Pollack JS, Ruyb AJ, Drenser KA, Williams GA, Sarrafzadeh R. Vitrectomy for a symptomatic lamellar macular hole. *Ophthalmology*2007;115:884-6 | 3. Casparis H, Bovey EH. Surgical treatment of lamellar macular hole associated with epimacular membrane. *Retina*2011;31:1783-90. doi:10.1097/IAE.0b013e31820a6818 | 4. Engler C, Schaal KB, Höh AE, Dithmar S. Surgical treatment of lamellar macular hole. *Ophthalmologie*2008;105:836-9. doi: 10.1007/s00347-008-1765-4 | 5. Androudi S, Stangos A, Brazitikos PD. Lamellar macular holes: tomographic features and surgical outcome. *Am J Ophthalmol*2009;148:420-6 | 6. Kalvoda, J. Vitreoretinal interface in relation to surgery on macular disorders. Dissertation work, First Faculty of Medicine, Charles University in Prague:2012;59 p | 7. Witkin AJ, Ko TH, Fujimoto JG, Schuman JS, Bajkal CR, Rogers AH, Reichel E, Duker JS. Redefining lamellar holes and vitreomacular interface: An Ultrahigh-resolution optical coherence tomography study. *Ophthalmology* 2006;113:388-97 | 8. Haouchine B, Kasein P, Tadayoni R, Erginay A, Gaudric A. Diagnosis of macular pseudoholes and lamellar macular holes by optical coherence tomography. *Am J Ophthalmol*2004;138:732-9 | 9. Peyman GA, Cheema R, Conway MD. Triamcinolone acetonide as an aid to visualization of the vitreous and the posterior hyaloids during pars planovitrectomy. *Retina*2000;5:554-5 | 10. Sakamoto T, Miyazaki M, Hisatomi T, Nakamura T, Ueno A, Itava K, Ishibashi T. Triamcinolone-assisted pars planovitrectomy improves the surgical procedures and decreases the postoperative blood-ocular barrier breakdown. *Graefes Arch Exp Ophthalmol*2002;240:423-9 | 11. Sonoda K H, Sakamoto T, Enaida H, Miyazaki M, Noda Y, Nakamura T, Ueno K, Yokoyama M, Kubota T, Ishibashi T. Residual vitreous separation visualized by intravitreal triamcinolone acetonide. *Ophthalmology*2004;111:226-30 | 12. Doi N, Uemura A, Nakao K, Sakamoto T. Vitreomacular adhesion and the defect in posterior vitreous cortex visualized by triamcinolone-assisted vitrectomy. *Retina*2005;25:742-5 | 13. Kalvoda J, Dušková J, Kuběna A, Povýšil C, Kalvodová B. Morphometry of surgically removed internal limiting membrane during vitrectomy in diabetic macular edema. *Graefes Arch Clin Exp Ophthalmol*2009;247:1307-14 | 14. Duncan RO, Sample PA, Weinreb RN, Bowd C, Zangwill LM. Retinotopic Organization of Primary Visual Cortex in Glaucoma: Comparing fMRI Measurements of Cortical Function with Visual Field Loss. *Prog Retin Eye Res*2007;26:38-56 | 15. Lešťák J, Tintěra J, Kynčl M, Svatá Z, Obenberger J, Saifrtová A. Changes in the Visual Cortex in Patients with High-Tension Glaucoma. *J Clin Exp Ophthalmol*2011;S4doi: 10.4172/2155-9570.S4-002 | 16. Lešťák J, Tintěra J, Svatá Z, Ettler L, Rozsival P. Glaucoma and CNS. Comparison of fMRI-Results in Hypertension and Normal Tension Glaucoma. *Biomed Pap Med Fac Univ Palacky Olomouc Czech Repub*2014;158:144-53 | 17. Sunnes JS, Liu T, Yantis S. Retinotopic mapping of the visual cortex using functional magnetic resonance imaging in a patient with central scotomas from atrophic macular degeneration. *Ophthalmology*2004;111:1595-8 | 18. Lešťák J, Tintěra J, Karel I, Svatá Z, Rozsival P. fMRI in Patients with Wet Form of Age-Related Macular Degeneration. *Neuro-Ophthalmol*2013;37:192-8. doi: 10.3109/016581072013.819581 | 19. Nguyen TH, Stievenart JL, Saucet JC, Le Gargasson JF, Cohen YS, Pelegri-Isaac M, Burnod Y, Iba-Zizen MT, Cabanis EA. Cortical response to age-related macular degeneration (part I). Methodology and subject specificities. *J Fr Ophtalmol*2004;27:65-71 | 20. Baseler HA, Gouws A, Crossland MD, Leung C, Tufail A, Rubin GS, Morland AB. Objective visual assessment of antiangiogenic treatment for wet age-related macular degeneration. *Optom Vis Sci*2011;88:1255-61 | 21. Baba T, Yamamoto S, Kimoto R, Oshitari T, Sato E. Reduction of thickness of ganglion cell complex after internal limiting membrane peeling during vitrectomy for idiopathic macular hole. *Eye (Lond)*2012;26:1173-80. doi:10.1038/eye.2012. Epub 2012 Aug 17. | 22. Kumagai K, Hangai M, Larson E, Ogino N. Progressive changes of regional macular thickness after macular hole surgery with internal limiting membrane peeling. *Invest Ophthalmol Vis Sci*2013;54:4491-7 | 23. Sevim MS, Sanigoglu H. Analysis of retinal ganglion cell complex thickness after Brilliant Blue-assisted vitrectomy for idiopathic macular holes. *Curr Eye Res*2013;38:180-4. doi: 10.3109/02713683.2012.738845. Epub 2012 Oct 24 | 24. Clark A, Balducci N, Pichi F, Veronese C, Morara M, Torrazza C, Ciardella AP. Swelling of the arcuate nerve fiber layer after internal limiting membrane peeling. *Retina* 2012;32:1608-13. doi: 10.1097/IAE.0b013e3182437e86 | 25. Lesnik Oberstein SY, Lewis GP, Chapin EA, Fisher SK. Ganglion cell neurites in human idiopathic epiretinal membranes. *Br J Ophthalmol*2008;92:981-5 | 26. Tsui E, Fujikawa A, Miyamura N, Yamada K, Mishima K, Kitaoka T. Visual field defects after macular hole surgery with indocyanine green-assisted internal limiting membrane peeling. *Am J Ophthalmol*2007;143:704-5 | 27. Tadayoni R, Svorenova I, Erginay A, Gaudric A, Massin P. Decreased retinal sensitivity after internal limiting membrane peeling for macular hole surgery. *Br J Ophthalmol*2012;96:1513-6. doi:10.1136/bjophthalmol-2012-302035 | 28. Terasaki H, Miyake Y, Nomura R, Piao CH, Hori K, Niwa T, Kondo M. Focal macular ERGs in eyes after removal of macular ILM during macular hole surgery. *Invest Ophthalmol Vis Sci*2001;42:229-34 | 29. Spiter Cornish K, Lois N, Scott N, Burr J, Cook J, Boachie C, Tadayoni R, la Cour M, Christensen U, Kwok A. Vitrectomy with internal limiting membrane (ILM) peeling versus vitrectomy with no peeling for idiopathic full-thickness macular hole (FTMH). *Cochrane Database Syst Rev*2013;5:6:CD009306 | 30. Jaissle GB, Bartz-Schmidt KU, Szurman P. Optic atrophy subsequent to epiretinal triamcinolone deposits in an eye following inner limiting membrane peeling. *Ophthalmology*2008;105:575-7 |